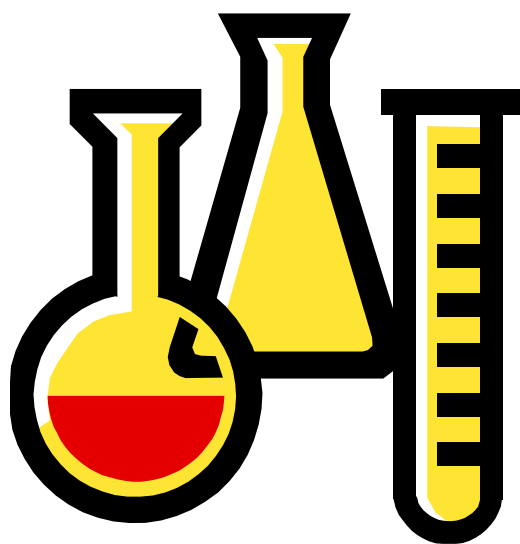


THE OHIO STATE UNIVERSITY

---

32nd Annual  
Mallory-Coleman  
Resident Research Day



Friday, April 9, 2004  
7:30 am

Blackwell Hotel  
OSU Campus

---

## PROGRAM

- 7:30 am Refreshments
- 7:45 am Welcome and Introduction
- 8:00 am Chris Nicholson, M.D.  
*“Failure of Nonoperative Treatment for Insertional Achilles Tendinosis”*
- 8:15 am Mark D’Onofrio, M.D.  
*“The Short-Term Outcome of Cryopreserved Anterior Tibialis Tendon Allograft Anterior Cruciate Ligament Reconstructions”*
- 8:30 am David Hoang, M.D.  
*“Antibiotic Elution From Calcium Sulfate Bulk Form Vs. Beads”*
- 8:45 am Lynn Rawcliffe, D.P.M.  
*“Early Stage Intervention of Charcot Neuroarthropathy With External Fixation”*
- 9:00 am Alicia Bertone, D.V.M., Ph.D.  
*“RGD Modified Adeno-Associated Virus Type 2 (AAV2) Vector Provides Expanded Tropism to Articular Cells”*
- 9:15-9:30 *Break*
- 9:30 am Alexandra Dale, M.D.  
*“Arthroscopic Management of Impingement of the Infrapatellar Fat Pad”*
- 9:45 am Julie Bishop, M.D.  
*“Cuff Integrity Following Arthroscopic Versus Open Rotator Cuff Repair: A Prospective Study”*
- 10:00 am Warren Harding III, M.D.  
*“A New Clinical Test for Avulsion of the Insertion of the Biceps Tendon”*
- 10:15 am Mario Ferretti, M.D.  
*“Anti-Inflammatory Effects of Continuous Passive Motion on Arthritic Menisci in Rabbits”*
-

- 10:30 am Terri Zachos, D.V.M  
*"Sustained Bone Morphogenetic Protein 2 Expression by Equine Bone Marrow Derived Mesenchymal Stem Cells in Three-Dimensional Culture"*
- 10:45-11:00 Break
- 11:00 am Steven Arnoczky, D.V.M., Visiting Professor and Moderator  
*"Basic Science of ACL Reconstructions: Implications of Rehab on Graft Remodeling"*
- 12:00 *Lunch*
- 1:00 pm Chris Karanfilov  
*"Articulating Loading Produces Significantly Different Acetabular Cup Micromotion Than Uniaxial Loading"*
- 1:15 pm Nicholas Iagulli  
*"A Simple and Accurate Method of Leg Length Determination During Total Hip Arthroplasty"*
- 1:30 pm Jeffrey Salin, D.O..  
*"Acute Gouty Arthropathy After Total Knee Arthroplasty"*
- 1:45 pm Thomas Smith, D.O.  
*"Total Hip Arthroplasty Dislocation Rates Can Be Decreased with Enlarged Femoral Heads and the Anterolateral Approach"*
- 2:00 pm Amelia Munsterman, D.V.M.  
*"Anti-Inflammatory Mechanisms of Alpha-Linolenic Acid on Lipopolysaccharide Induced Equine Synovitis in Vitro"*
- 2:15 pm Lynette Mehl, D.P.M.  
*"Treatment of Recalcitrant Intermetatarsal Neuroma With 4% Sclerosing Alcohol Injection"*
- 2:30 pm End of Day
-

## **MALLORY-COLEMAN DAY**

Mallory-Coleman resident research day was established in 1972 in memory of Katherine Virginia Mallory and Sally Jo Coleman.

This research day was established in order to encourage the development of ideas related to research in orthopaedic surgery and basic science. In accordance with the curriculum for both the OSU Orthopaedic and Podiatric residency programs, each chief resident is required to present his or her research project during this forum.

Each year, a distinguished visiting professor from an outside institution is invited to moderate and analyze the resident presentations and abstracts as well as provide constructive criticism and commentary for each resident presentation.

### **Past Visiting Professors Include:**

2003 Joseph Buckwalter, M.D.  
2002 Victor Goldberg, M.D.  
2001 James Urbaniak, M.D.  
2000 Douglas Jackson, M.D.  
1999 Douglas Dennis, MD  
1998 Thomas Einhorn, MD  
1997 Larry S. Matthews, MD  
1996 Gary Friedlander, MD  
1995 James Herndon, MD  
1994 Clement B. Sledge, MD

## **2004 MALLORY-COLEMAN VISITING PROFESSOR AND MODERATOR:**

### **STEVEN ARNOCZKY, D.V.M.**



Dr. Arnoczky is currently a Professor of Orthopaedic Surgery at the Michigan State University College of Human Medicine as well as the College of Osteopathic Medicine. He is also the Director of the Laboratory for Comparative Orthopaedic Research in the College of Veterinary Medicine at Michigan State University. He graduated from The Ohio State University with a degree in Biology then went on to The Ohio State University College of Veterinary Medicine where he was awarded the degree of Doctor of Veterinary Medicine. He did both his rotating internship and his veterinary surgical residency at The Animal Medicine Center in New York.

He has held numerous research positions since completing his residency in 1975, including scientist positions at The Hospital for Special Surgery and Cornell University. He has also held numerous professor titles in surgery and orthopaedics at institutions including Louisiana State University and Cornell. Dr. Arnoczky also served as the Director of the Laboratory for Comparative Orthopaedic Research at the Hospital for Special Surgery.

Dr. Arnoczky has extensive teaching experience, having mentored innumerable post-doctoral fellows, visiting residents, research fellows, and undergraduates. He has received approximately 100 research grants over the years.

He is on the editorial board of several journals, including the Journal of Bone and Joint Surgery and the Journal of Orthopaedic Research. He has received numerous honors and awards for research excellence and has received the Distinguished Alumni Award from both The Ohio State University and the Hospital for Special Surgery.

Dr. Arnoczky has published 240 peer-reviewed scientific articles and abstracts and has 73 books and book chapters.



*Chris Nicholson, M.D. is  
a PGY4 Resident in  
Orthopaedics at The Ohio  
State University*

## **FAILURE OF NONOPERATIVE TREATMENT FOR INSERTIONAL ACHILLES TENDINOSIS**

Authors: Chris Nicholson, M.D., Gregory Berlet, M.D.,  
Thomas Lee, M.D.  
Presenter: Chris Nicholson, M.D.

The purpose of this paper was to review a series of patients with insertional tendinopathy, to determine whether magnetic resonance (MR) imaging stratification could predictably determine which patients ultimately would fail nonoperative treatment

Over a three year period, 157 patients were seen for insertional posterior heel pain. These charts were retrospectively reviewed. All patients who required surgery underwent MR imaging, as did many of those who responded to nonoperative treatment. Each patient who had been evaluated with MR was stratified according to a classification system of tendinosis based on size of tendon and degree of involvement. Sagittal STIR images were employed for the classification. Patients who required surgery underwent a standard two-incision decompression and debridement. Postoperative care was standardized.

Of the 157 patients with insertional heel pain, 83 (53%) responded to nonoperative treatment. Of those who had undergone MR imaging in this group, most were graded as Type I. The remaining 74 patients (47%) required surgical intervention after average of 12 months of conservative treatment. A significant improvement in AOFAS hindfoot score was noted after surgery. Most patients were satisfied. Complications were infrequent.

Overall, of the 16 patients whose MRI was categorized as Type I, only 2 (12.5%) went on to surgery. 59 of the 65 Type II patients (90.8%) had subsequent surgical intervention. Finally, 19 of the 27 patients (70.4%) graded as Type III required surgery. Thus, the percentage of patients going to surgery varied significantly with MRI findings.

Patients with tenderness of the Achilles tendon insertion without obvious signs of inflammation and who demonstrate confluent areas of intrasubstance signal changes on MRI (suggestive of tendinosis) do not respond to nonoperative care. Early identification of these patients and surgical intervention may lead to earlier return to function and avoidance of weakness and loss of proprioception associated with nonoperative treatment.



*Mark D'Onofrio, M.D.  
is a PGY5 Resident in  
Orthopaedics at The  
Ohio State University*

## ***THE SHORT-TERM OUTCOME OF CRYOPRESERVED ANTERIOR TIBIALIS TENDON ALLOGRAFT ANTERIOR CRUCIATE LIGAMENT RECONSTRUCTIONS***

Authors: Mark D'Onofrio, M.D., Scott Van Steyn, M.D., David Kovacevic

Presenter: Mark D'Onofrio, M.D.

### **Abstract**

#### **Background**

Recent interest in the use of allograft tissue in ACL reconstruction has been controversial. The purpose of this study was to evaluate the short term results of ACL reconstructions utilizing a cryopreserved allograft tendon in a consecutive patient series

#### **Methods**

53 consecutive patients underwent primary ACL reconstruction between July 2000 and December 2001. All patients received a cryopreserved anterior tibialis tendon allograft fixed with an endo-button proximally and a bioabsorbable screw distally. These patients were evaluated at a minimum of 2 year follow-up with the Lysholm knee score and objective data if available.

#### **Results**

The average age of participants was 33 years of age. Follow-up averaged 2.6 years (27-43onths). 26 patients completed the subjective Lysholm questionnaire with an average score of 94 (84-100). 12 patients were able to be examined. There range of motion was 98% of the normal knee. Greater than 90% of patients had KT-1000 measurements within 3 mm of the unaffected knee. Single leg hop tests were also greater than 90% of normal in the majority of patients.

#### **Conclusion**

The use of allograft tendon in ACL reconstruction performed as well as autograft material in the short-term period without having the possible complications associated with autograft harvesting. It remains to be seen if these grafts will perform as well in the long-term.



*David Hoang, M.D. is  
a PGY5 Resident in  
Orthopaedics at Mt.  
Carmel*



*Lynn Rawcliffe, D.P.M.  
is a PGY3 Resident in  
Podiatry at The Ohio  
State University*

## **ANTIBIOTIC ELUTION FROM CALCIUM SULFATE BULK FORM VS. BEADS**

Authors: David Hoang, M.D.  
Presenter: David Hoang, M.D.

Calcium sulfate has been previously studied as an antibiotic carrier. The effect of carrier size on antibiotic release was studied in vitro. Calcium sulfate was loaded with tobramycin. In one group, one large sphere was formed. In another group, 58 beads, with equivalent weight and tobramycin concentration were created. Finally, a control group of tobramycin-loaded PMMA beads was studied. Tobramycin was rapidly released from the calcium sulfate beads. After day 1, tobramycin release from the calcium sulfate sphere remained higher than the calcium sulfate beads for the remainder of the study. PMMA beads demonstrated the most consistent tobramycin release. Plaster of Paris is an effective antibiotic carrier. In vitro, bulk form calcium sulfate eluted antibiotics at a higher level than bead form. This higher level of elution is potentially advantageous in treating bone infections. Further studies in vivo need to be carried out to confirm efficacy.

## **EARLY STAGE INTERVENTION OF CHARCOT NEUROPATHY WITH EXTERNAL FIXATION**

Authors: Lynn Rawcliffe, D.P.M., Alan Block, D.P.M., M.S.  
Presenter: Lynn Rawcliffe, D.P.M.

Charcot neuroarthropathy can be a challenging entity to the foot and ankle surgeon, especially when ulceration and infection are present. There is an evolution of management from prolonged immobilization and nonoperative means to early operative intervention in the acute stages. Most recently, fine-wire external fixation has been described for the stabilization and reconstruction of the Charcot foot. The authors reviewed 15 patients with midfoot Charcot collapse in the acute and coalescence stages who underwent debridement, and placement of external fixation with and without corrective osteotomy. All but one patient was transitioned from the external fixator into corrective footwear without further collapse or ulceration at the end of a 12-month follow-up. We support the use of external fixation to arrest progressive degeneration in early stages of charcot degeneration; Furthermore, we feel it is presently the only comprehensive approach that can simultaneously address infection, deformity and soft tissue defect in the charcot foot and ankle.



*Alicia Bertone, D.V.M.,  
Ph.D. is a Professor of  
Veterinary Medicine and  
Professor of Equine  
Orthopaedic Surgery at  
The Ohio State University*

## **RGD MODIFIED ADENO-ASSOCIATED VIRUS TYPE 2 (AAV2) VECTOR PROVIDES EXPANDED TROPISM TO ARTICULAR CELLS**

Authors: Alicia L Bertone, DVM, PhD; Weisong Gu, PhD; Wenfang Shi, PhD; Terri A Zachos, DVM; Jeffrey S Bartlett, PhD  
Presenter: Alicia Bertone, DVM.

### **INTRODUCTION**

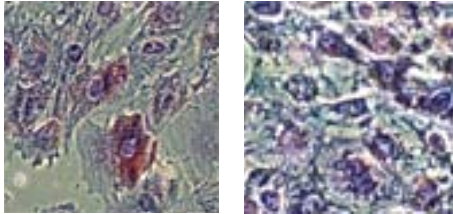
Adeno-associated virus type-2 (AAV-2) gene transfer vectors have shown great promise for human gene therapy due to the stability of gene expression, lack of significant immune response and efficiency of gene transfer. However, conditions may limit transduction of certain cell types, including low expression of the required cell surface receptor for AAV-2 entry, heparan sulfate proteoglycan. Targeting virus to alternative cell surface receptors using the RGD motif as the targeting peptide has successfully improved efficiency of Adenoviral gene delivery in joints<sup>1</sup> and bone marrow cells<sup>2</sup>, and for AAV-2 in cancer cell lines.<sup>3</sup> The goal of our study was to compare the cell surface receptor profiles of HSPG and integrins to the transduction efficiencies for rAAV-2 and rAAV-2-RGD using articular cell types present in joints with subchondral injury, specifically chondrocytes, synovial cells, and bone marrow-derived mesenchymal stem cells. Our hypothesis was that rAAV-2 modified with the RGD motif will more efficiently transduce articular cell types that have lower surface expression of HSPG and higher surface expression of integrins. RAAV-RGD may improve our gene transfer efficiency for AAV-2 in articular cells.

### **MATERIALS AND METHODS**

Articular chondrocytes, synovial membrane cells, and bone marrow-derived mesenchymal stem cells were harvested from adult healthy horses with no evidence of joint disease. Articular cartilage was also harvested from diseased knee joints at sites of osteochondrosis desiccans (OCD), a developmental orthopedic disease in horses and humans.<sup>4</sup> Articular cartilage and synovial membrane were obtained from knee joints, digested in 0.1% collagenase, filtered, and expanded in monolayer culture in L-glutamine supplemented DMEM, 10% FBS and antibiotics. Bone marrow was obtained from the sternum and similarly cultured in flasks. Primary expanded cells were frozen at -80C for subsequent studies. We confirmed the pluripotentiality of our bone marrow-derived (BMD) cells by culture in controlled osteogenic, chondrogenic and adipogenic medium cocktails containing dexamethasone with ascorbate, rhTGF- $\beta$ 1, and dexamethasone with insulin and indomethacin, respectively. Our BMD cells grown in these differentiating media stained for adipose phenotype with Oil Red O (Fig 1), osteogenic phenotype by alkaline phosphatase assay (Fig 2), and chondrogenic phenotype by staining with toluidine blue. Aliquots of all three cell types were thawed and grown to confluence in 48 well plates ( $1 \times 10^5$  cells/well). Triplicate wells were transfected for 4 hrs with either unmodified rAAV2 or the RGD modified rAAV2 containing the enhanced Green Fluorescent Protein gene [rAAV2-eGFP and rAAV2-A5884CRGD-eGFP, respectively] and returned to supplemented DMEM. This mutant vector contains the 4C-RGD epitope (CDCRGDCFC) located within the VP3 gene of the capsid ORF following amino acid 588 (VP1 numbering). This vector has previously been shown to direct cell transduction via an cell-surface integrin receptors.<sup>3</sup> GFP positive cells were photographed and counted as a percent of total live cells at days 2,5,7,14 and 21 to assess duration of and identify maximal gene expression. Cells ( $\sim 2 \times 10^6$ ) were harvested and briefly incubated at 37C to allow regeneration of surface integrin and then incubated with FITC-labeled LM609 antibody (aVb3) or FITC-labeled P1F6 antibody (aVb5) (1:200 dilution) for 2 h at 4C, washed with HEPES buffered saline 5X and analyzed by flow cytometry. For analysis of HSPG expression, cells were incubated with anti-HSPG monoclonal antibody, HepSS-1, for 2h at 4C and similarly processed.<sup>3</sup>



## RGD MODIFIED ADENO-ASSOCIATED VIRUS TYPE 2 (AAV2) VECTOR PROVIDES EXPANDED TROPISM TO ARTICULAR CELLS, CONTD....



### RESULTS AND DISCUSSION

Chondrocytes minimally expressed HSPG as compared to HeLa cells, and similarly to other non-permissive cells.<sup>3</sup> Chondrocytes express integrin avb3, but not avb5, indicating that the internalization of the mutant virus via the RGD-rich region would likely target chondrocytes via avb3 integrin to expand the tropism of AAV-2 vector to these cells. Correspondingly, rAAV-A5884C-RGD transduced chondrocytes 100X more efficiently at low MOI and 10X more efficiently at high MOI than unmodified rAAV-2, achieving biologically relevant % cell transductions (25%) at MOI as low as 10. Diseased chondrocytes transduced less efficiently than normal chondrocytes.

The surface receptor expression of heparan-sulfate proteoglycan and integrins are different among bone marrow-derived multipotent cells, synovial cells and chondrocytes. (Fig 4 below) BMD cells have greater HSPG and less integrin expression than chondrocytes. The presence of integrin receptors explains the modest expanded transfection efficiency with rAAVA5884C-RGD over rAAV2 in BMD cells. The lower integrin expression, as compared to chondrocytes, explains the 2-fold rather than 100-fold increase in transfection efficiency seen with AAVA5884C-RGD in BMD cells as compared to chondrocytes. (Figs 5&6) Synovial cells had modest HSPG and no avb3 integrin expression, possibly explaining lower transfection efficiency of normal synovium *in vivo* with AAV.

Fig. 3

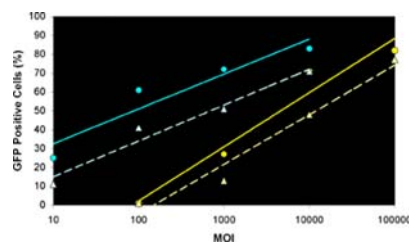
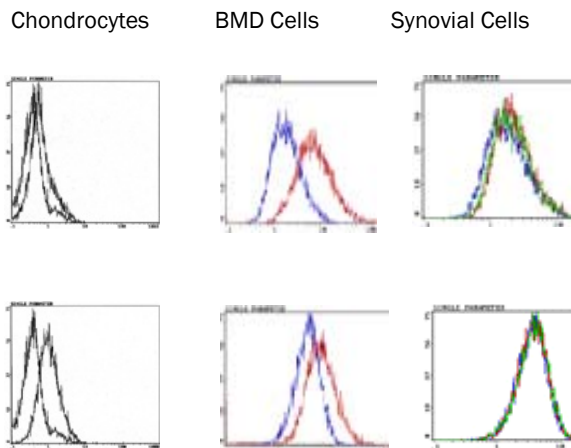


Figure 4



Continued on Next Page...

## RGD MODIFIED ADENO-ASSOCIATED VIRUS TYPE 2 (AAV2) VECTOR PROVIDES EXPANDED TROPISM TO ARTICULAR CELLS, CONTD.

Fig 5.(Below)(20X). GFP<sup>+</sup> chondrocytes were > 70% at  $1 \times 10^3$  virus/cell with AAVA5884C-RGD mutant (right) and poor with rAAV-2 vector (left).

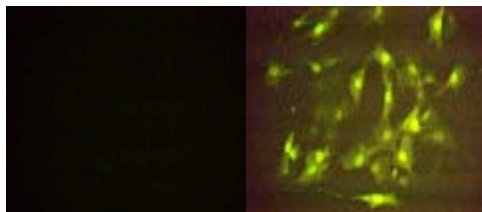



Fig 6. (Below)(40X). BMD cells were 100X less permissive than chondrocytes with AAV-RGD, but efficiency of transduction doubled (right) over rAAV2 (left).



### REFERENCES:

- 1) Bakker AC, Van de Loo FA, Joosten LA, et al. A tropism-modified adenoviral vector increased the effectiveness of gene therapy for arthritis. *Gene Therapy* 2001;8:1785-93.
- 2) Tsuda H, Wada T, Ito Y, et al. Efficient BMP2 gene transfer and bone formation of mesenchymal stem cells by a fiber-mutant adenoviral vector. *Mol Ther* 2003;7:354-65.
- 3) Shi W, Bartlett JS. RGD inclusion in VP3 provides adeno-associated virus type 2 (AAV2)-based vectors with a heparan sulfate-independent cell entry mechanism. *Mol Ther* 2003;7:515-515-25.
- 4) Semevolos SA, Brower-Toland BD, Bent SJ, et al. Parathyroid hormone-related peptide and Indian hedgehog expression patterns in naturally acquired equine chondrosis. *J Orthop Res* 2002;20:1290-7.



*Alex Dale, M.D. is a  
PGY5 Resident in  
Orthopaedics at The  
Ohio State University*

## **ARTHROSCOPIC MANAGEMENT OF IMPINGEMENT OF THE OF THE INFRAPATELLAR FAT PAD**

Authors: J. Alexandra Dale, M.D., Scott Van Steyn, M.D.  
Presenter: Alex Dale, M.D.

Hoffa's Disease or impingement of the infrapatellar fat pad has long been recognized as a significant yet often overlooked cause of anterior knee pain. Since the initial description in 1904 by Albert Hoffa, the English literature has been largely based on isolated case reports and clinical observations.

We are reporting the results of six knees diagnosed with Hoffa's Disease and managed arthroscopically. The diagnosis was based on patient history and clinical exam after exclusion of other causes of anterior knee pain. All patients underwent an appropriate trial of conservative therapies. During arthroscopy, the diagnosis was confirmed by excluding any other intraarticular pathology. The patients were evaluated both pre- and post-operatively using the modified Cincinnati Knee Rating System. There was a significant improvement in their symptoms and function after surgery and in follow-up.

In patients with positive clinical and surgical findings, excellent results can be expected from selective arthroscopic resection of a pathologic fat pad.



*Julie Bishop, M.D.  
is an Associate with  
Columbus Bone,  
Joint, and Hand  
Surgeons*

## **CUFF INTEGRITY FOLLOWING ARTHROSCOPIC VERSUS ROTATOR CUFF REPAIR: A PROSPECTIVE STUDY**

Authors: Julie Bishop MD, Steven Klepps MD, Ian K. Lo MD,  
Justin Bird MS, James N Gladstone MD, Evan L Flatow MD.  
Presenter: Julie Bishop, M.D.

Arthroscopic rotator cuff repair (RCR) has been reported to have good clinical results but 70% to 90% retear rates by ultrasound. This study prospectively assesses postoperative cuff integrity and outcome following arthroscopic RCR, and compares these results to open RCR.

Fifty-five consecutive patients after arthroscopic RCR by a single surgeon were prospectively enrolled for evaluation preoperatively and at one year follow-up, including a postoperative MRI. A prior prospective study of open RCR by the same surgeon was used for comparison.

There were 32 patients in the open RCR group, and 40 completed the arthroscopic RCR protocol. ASES scores improved from 40 to 85 in the open group and from 46 to 84 in the arthroscopic group, and Constant scores from 53 to 80 in the open group and from 52 to 75 in the arthroscopic group ( $p < 0.0001$ ). 69% of the open and 53% of the arthroscopic group were intact by MRI. Of tears  $< 3$ cm, 74% in the open and 84% in the arthroscopic group were intact. Of tears  $> 3$ cm, 62% were intact in the open group and only 24% in the arthroscopic group. This difference was significant with  $p = 0.036$ . There was a trend towards better scores with an intact cuff than with a retear in both groups, however this only reached significance ( $p < 0.03$ ) in the arthroscopic group when evaluating the ASES score, (Constant 79, ASES 89 – when intact and Constant 72, ASES 75 – when return). In the arthroscopic group, patients with intact cuffs had significantly greater strength of elevation ( $p = 0.01$ ) and external rotation ( $p = 0.02$ ).

Open and arthroscopic RCR had similar outcomes. Cuff integrity was comparable for small tears, but the retear rate for large tears was twice as high after arthroscopic repair.



*Warren Harding III, M.D.  
is an Orthopaedic Shoulder  
Surgeon with Wellington  
Orthopaedics and Sports  
Medicine in Cincinnati*

## **A NEW CLINICAL TEST FOR AVULSION OF THE INSERTION OF THE BICEPS TENDON**

Authors: Warren Harding III, M.D.

Presenter: Warren Harding III, M.D.

*Introduction:* Avulsion of the biceps tendon at the radial tuberosity is a relatively uncommon problem. The diagnosis can be missed unless the physician maintains a high index of suspicion and a careful history and physical examination are completed. MRI assessment may be required for confirmation.

*Materials and Methods:* Twenty-eight patients presenting with elbow injuries were tested in the clinic. Fourteen consecutive patients with MRI assessment of the elbow for problems other than suspected or confirmed avulsion of the biceps insertion; seven with MRI documented biceps insertion avulsions; seven with clinically diagnosed rupture of the long head of the biceps by history and physical exam.

*Results:* The biceps' belly was noted to rise visibly and palpably in the arm with active and passive supination, return to a normal position with return to neutral rotation and then flatten and move to a more distal position with pronation in patients without a biceps tendon insertion avulsion. In those patients with MRI documented biceps insertion avulsions, the proposed test revealed the absence of the rise and fall of the muscle belly with passive supination and pronation of the forearm.

*Conclusions:* The test described is a valid and helpful test when acute or chronic discontinuity of biceps tendon of insertion needs to be confirmed or ruled out.

*Clinical Relevance:* Utilization of this test can decrease the chance for either over or under diagnosing the problem without having to resort to MRI assessment, or when MRI assessment is not possible.



*Mario Ferretti, M.D. is a Post Doctoral Researcher in the Department of Oral Biology at The Ohio State University College of Dentistry*

## ANTI-INFLAMMATORY EFFECTS OF CONTINUOUS PASSIVE MOTION ON ARTHRITIC MENISCI IN RABBITS

Authors: M. Ferretti, A. Srinivasan, F. Baliko, J. Deschner, R. Gassner, R.B. Salter, and S. Agarwal

Presenter: Mario Ferretti, M.D.

**Introduction:** Overloading of the joints that are associated with osteoarthritis exerts catabolic and proinflammatory effects on articular tissues, such as cartilage, meniscus, and synovial membrane. However, physiological loading of cartilage is a necessity for cartilage homeostasis and continuous passive motion (CPM) has been successfully applied for stimulating the healing of articular and periarticular tissues.

**Objective:** Since little is known about the mechanisms of CPM effects on meniscus we determined the biomolecular effects of CPM and immobilization (IM) on menisci in antigen-induced arthritis (AIA).

**Material and Methods:** AIA was caused with bovine serum albumin (BSA) in white male New Zealand rabbits. The right knee of the rabbits was subjected to CPM on a special apparatus. The right knee of another group of rabbits was immobilized by splinting. After 24 and 48 hours of passive exercise and immobilization, respectively, the articular tissues were harvested for immunohistochemistry using antibodies against interleukin (IL)-1b, IL-10, matrix metalloproteinase (MMP)-1, cyclooxygenase (COX)-2, and glycosaminoglycans (GAG).

**Results:** CPM stimulated the healing of AIA but IM did not. The synthesis of IL-1, MMP-1 and COX-2 in menisci was markedly lower in the CPM group compared with the IM knees. In addition to the suppressed production of proinflammatory and catabolic mediators, the synthesis of the antiinflammatory cytokine IL-10 was upregulated in the menisci, thereby enhancing the suppression of the inflammatory process in arthritis. Immunohistochemical analysis of GAG content in arthritic menisci revealed that CPM also suppressed fibrocartilage degradation. These results are also supported by our findings obtained from immunohistochemical analysis in arthritic synovia and cartilage.

**Conclusion:** These data show that CPM generates potent anti-inflammatory and reparative signals in arthritic menisci and unravel biomolecular events used by CPM.



*Terri Zachos, D.V.M. is  
a Graduate Research  
Associate in Veterinary  
Medicine at The Ohio  
State University*

## **SUSTAINED BONE MORPHOGENETIC PROTEIN 2 EXPRESSION BY EQUINE BONE MARROW-DERIVED MESENCHYMAL STEM CELLS IN THREE-DIMENSIONAL CULTURE**

Authors: Terri Zachos, DVM, Alicia Bertone, DVM  
Presenter: Terri Zachos, DVM

Biodegradable carriers have been used as three-dimensional (3D) matrices for delivery of cells genetically modified to express growth factors to sites of impaired fracture healing. The purpose of this study was to transduce equine bone marrow-derived mesenchymal stem cells (BMDMSC) with the gene encoding human bone morphogenetic protein (BMP) 2, and to evaluate protein production in 3D culture. Our hypothesis was that 3D culture would support increased BMP2 production. Cells were assigned to four groups: 1) no-vector control (No Ad), 2) reporter gene construct encoding beta-galactosidase (AdLacZ); 3) reporter gene construct encoding luciferase (AdLuc); 4) Ad-hBMP2 vector. Adenoviral vectors were applied at a multiplicity of infection of 100:1. Cells were suspended in 1.2% alginate. Quantification of BMP2 was performed using an ELISA at days 0, 2, 12, and 22. Means were compared using two-way ANOVA. Luciferase expression was quantified at days 1, 2, 12, and 22 using *in vivo* imaging. Values were compared using student's t-test. A *P*-value of <0.05 was considered significant for all analyses. Cytomorphometric evaluations were performed on fixed specimens. Luciferase expression was greatest at day 1. Significant differences were noted at days 1 (*P*<0.000004) and 2 (*P*<0.005). Transduction was confirmed by BMP2 increases at days 2 (*P*<0.03), 12 (*P*<0.00006), and 22 (*P*<0.000003), but bone formation was not induced. Expression of BMP2 by genetically modified BMDMSC in 3D culture was achieved. Use of a novel reporter gene was validated. This system may be useful for the delivery of BMP2-producing cells to stimulate bone formation by host cells.



*Chris Karanfilov is a  
Graduate Research  
Associate in Biomedical  
Sciences at The Ohio  
State University*

## **“ARTICULATING LOADING PRODUCES SIGNIFICANTLY DIFFERENT ACETABULAR CUP MICROMOTION THAN UNIAXIAL LOADING”**

Authors: Chris I. Karanfilov, Alan S. Litsky, M.D., Sc.D.

Presenter: Chris Karanfilov

**Introduction:** Polyethylene (PE) wear debris is the dominant factor in the late-term loosening of total hip arthroplasties and the leading problem necessitating revision surgery. Particles generated from the joint side of the implant account for a substantial portion of the debris, but backside wear (occurring at the articulation between the metal cup and the PE liner) also contributes to the problem. Backside wear has been correlated with the amount of micromotion at this interface. The goals of this project were to refine and extend a technique previously used in our laboratory for measuring micromotion between the acetabular cup and the polyethylene liner under uniaxial loading to measure backside micromotion under “articulating” conditions. The hypothesis was that the both the amount and direction of the micromotion would be substantially different.

**Specific Aims:** Quantify the “worst-case” micromotion between the PE liner and the metal acetabular shell with changing load vectors and compare the pattern and magnitude with micromotion data obtained under uniaxial loading

**Methods:** Custom-fabricated fixtures welded to the convex surface of the cup held spring-loaded LVDTs [Model LBB375PA-100, Lucas Schaevitz, Pennsauken, NJ] to the cup. The arm of the LVDTs were aligned with probes secured to the liner. Only relative motion between the two components was measured [1-5]. LVDTs were individually calibrated to assure an accuracy and reproducibility of approximately 1 micron.

Modular liners from seven different manufacturers had been tested previously under uniaxial cyclic loads up to 1732 N [2-5]. In this study, the extremes of articulation were simulated by a constant compressive load (1732 N) upon which a rotatory component ( $\pm 1000$  N) was superimposed to achieve a net force vector of 2000 N at  $\pm 30^\circ$  (Figure 1). Two different cup-liner systems [Pinnacle<sup>®</sup> and Duraloc<sup>®</sup>, DePuy, Warsaw, IN] used in prior studies were used to assess the effect that this loading had on micromotion. For each cup design a 54 mm OD cup without screw holes was obtained and two holes were drilled and deburred at diametrically opposite points in the periphery of the cup with care taken to avoid interference with any peripheral fixation mechanism. A series of four neutral liner were tested in each cup. The liner was loaded through a 28 mm diameter cobalt-chromium femoral head. Data was acquired for 10 consecutive loading cycles at 100 cycles, 1000 cycles, and then at 10,000 cycle intervals up to 200,000 cycles.

Load, displacement, and rotation data from the MTS and the voltage outputs from the LVDTs were acquired simultaneously. LVDT voltages were converted to micromotion using the calibration curves.

**Data and Discussion:** Most acetabular designs tested under uniaxial conditions have shown a settling in period of up to 50,000 cycles after which the micromotion remains stable (Figure 2). The data from the articulating micromotion measurements are distinctly different from the data obtained in previous experiments. Figure 3 shows the raw data from the eight liners tested in this manner. The most noticeable feature is the absence of the “run-in” period seen on axial loading experiments during which larger micromotion levels settled in towards a steady value over the first 50,000 cycles.

*Continued on Next Page*



## “ARTICULATING LOADING PRODUCES SIGNIFICANTLY DIFFERENT ACETABULAR CUP MICROMOTION THAN UNIAXIAL LOADING”, CONTD....

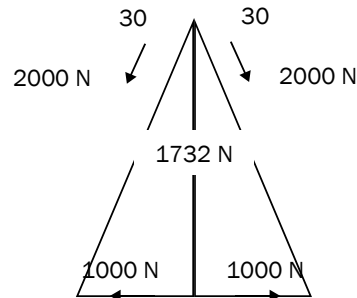


Figure 1

The second obvious feature is the larger values of micromotion obtained with this loading regimen. Finally, the liner-to-liner consistency seen in almost all axial loading experiments (with designs from multiple manufacturers) is not evident with the articulating loading. The variation from one data point to the next is significantly larger than seen under axial loading conditions. Only two the cups showed smooth data curves but the other six cups showed surprisingly irregular curves.

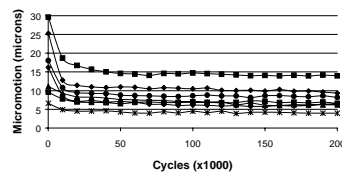


Figure 2: Micromotion of seven manufacturers' Cup-liner systems under uniaxial loading

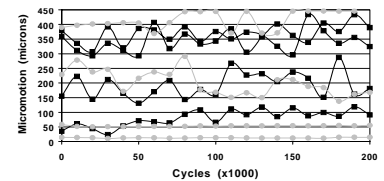


Figure 3: Micromotion under “articulating” loading conditions.

Because of the large scatter in the data, the average micromotion under “articulating” conditions (considering all data points) of the two designs tested is not statistically different: Pinnacle --  $246 \pm 134$ , Duraloc --  $170 \pm 182$  ( $p=0.52$  for two-tail t-test). Because the micromotion does not seem to stabilize, analysis of the end-point micromotion is no different from the average values: Pinnacle --  $246 \pm 135$ , Duraloc --  $171 \pm 195$  ( $p=0.55$  for two-tail t-test).

A re-evaluation of the experimental protocol was undertaken to seek explanations for these unexpected findings. Calibration curves were run for all of the LVDT's and readout/controller boxes and were found to be accurate and reproducible. A control study measuring the effect of intentional LVDT misalignment showed only a minimal effect on the data. Deformation to the internal contour of the cups secondary to the attachment of the mounting fixtures may have an effect but wouldn't explain the variation between the liners as all liners from each design were testing in the same cup with the same orientation.

**Conclusions:** The micromotion between the acetabular cup and the polyethylene liner under a simulation of articulating loading is distinctly different, and substantially greater, than the micromotion measured under axial loading. Liners do not seem to settle in to a steady state level of micromotion under these test conditions as they do under axial loading. The scatter between cups and among data points in a single run is much larger when tested under articulating conditions. This variability is not yet adequately explained. Simulated “articulating” loading produced a much more rigorous test for a cup-liner design than had previous studies using an axial loading. Evaluation of more cup-liner designs from other manufacturers is necessary to confirm this.





*Nicholas Iagulli, is a  
3rd Year Medical  
Student at The Ohio  
State University  
College of Medicine  
and Public Health*

## **A SIMPLE AND ACCURATE METHOD OF LEG LENGTH DETERMINATION DURING TOTAL HIP ARTHROPLASTY**

Authors: Nicholas Iagulli, Keith R. Berend, MD, Adolph V. Lombardi, Jr., MD, FACS, and Thomas H. Mallory, MD, FACS

Presenter: Nicholas Iagulli

The achievement of post-operative leg-length equality following total hip arthroplasty (THA) can be difficult. Patient factors such as obesity, height, gender, and diagnosis may play a role in the accuracy and ability to recreate normal leg lengths. Leg length discrepancy (LLD), or a perception thereof, is one of the leading reasons for malpractice liability in THA surgery. Most currently available methods of determining leg length intra-operatively require specialized instruments, many of which are difficult to use and have not been validated as accurate across a broad patient range. The purpose of this retrospective study was to determine the accuracy of pre-operative templating and intra-operative measurement of leg-length using the down side, well leg as the reference.

Pre-operatively a standardized AP pelvis radiograph is templated using the non-operative extremity as the reference. The center of rotation of the acetabulum is determined and marked. The femoral component template is then matched for canal diameter and implant size. The corresponding femoral neck osteotomy level is then marked. Femoral head implant neck length is then determined.

Intra-operatively the relative lengths of the extremities are measured with the patient supine. Once placed into the lateral decubitus position, the operative leg and well leg are placed to lie over one another with the feet and heels aligned symmetrically. The tibial tubercles of the well and affected limbs are palpated and the relative length difference is noted. This serves as a reference and is correlated with the pre-operative template. Once the acetabular and femoral components have been implanted, neck length is adjusted to recreate equal leg lengths based upon the resection level and the relative difference between the well leg and the operative leg.

This study is a pilot design of 71 randomly selected THA performed by 3 surgeons of varied experience with the technique. Only cases of unilateral hip disease were evaluated to avoid confounding issues of staged surgery. Using the transischial line as a reference, the pre-operative and post-operative differences in leg lengths were determined. Physical examination for leg length and patient report of significant LLD were also evaluated.

The average pre-operative LLD was 5.1mm (SD 10.0) of shortening of the operative extremity. Post-operatively, the LLD averaged 3.3mm (SD 6.3) of lengthening. There were 5 cases in which the leg was lengthened 15mm or more. Only one of these patients perceived a significant LLD and no significant LLD was identified on physical exam. Cases in which more than 1cm of lengthening occurred tended to be in cases in which the operative leg was longer preoperatively.

In this pilot study, the simple method of preoperative templating and well-leg reference for determination of leg lengths appears to provide acceptable results similar to those published for other methods in routine primary THA. We have begun a larger study of 500 THA to further investigate patient variables such as weight, BMI, height, gender and diagnosis, and surgeon experience that may add to or subtract from the accuracy of this technique.



*Jeffrey Salin, D.O. is a  
PGY3 Resident in  
Orthopaedics at Doctors  
Hospital—Stark  
County in Massillon,  
Ohio*

## **ACUTE GOUTY ARTHROPATHY AFTER TOTAL KNEE ARTHROPLASTY**

Authors: Jeffrey W. Salin, DO; Adolph V. Lombardi, Jr. MD, FACS; Keith R. Berend, MD; Douglas J. Chonko, MS, DO

Presenter: Jeffrey Salin, D.O.

Although gout is the most common inflammatory arthritis in men older than 40, cases reported following total knee arthroplasty are rare. In the complete development of its natural history, gout passes through four stages: (1) asymptomatic hyperuricemia, (2) acute gouty arthritis, (3) intercritical gout and (4) chronic tophaceous gout. The first attack is usually monoarticular and associated with few constitutional symptoms. Later attacks become polyarticular and associated with fever.

The incidence of gout varies in populations with overall prevalence of 1.6 to 13.6 per thousand. Gout is the most common inflammatory arthritis in men older than 40 years in the United States. In 1986 there were an estimated 2.2 million self-reported cases of gout.

To the authors' knowledge, a total of five cases of gout involving total knee arthroplasty (TKA) and two case reports involving total hip replacement have been reported. The current report presents three knees in two patients with gouty arthritis after total knee arthroplasty.

Individualized treatment should be based upon the clinical factors surrounding the attack as well as laboratory variables. The most critical aspect is ruling out infection as the etiology or concomitant issue. Treatment strategies from non-operative to aggressive surgical treatment are discussed.



*Thomas Smith, D.O. is  
a Clinical/Research  
Fellow at Joint Implant  
Surgeons and  
OrthoNeuro, Inc in  
Columbus*

## **TOTAL HIP ARTHROPLASTY DISLOCATION RATES CAN BE DECREASED WITH ENLARGED FEMORAL HEADS AND THE ANTEROLATERAL APPROACH**

Authors: Thomas M. Smith, DO; Keith R. Berend, MD; Adolph V. Lombardi Jr., MD, FACS; Thomas H. Mallory, MD, FACS; Joanne B. Adams, BFA

Presenter: Thomas Smith, D.O.

Post-operative dislocation is one of the major causes of morbidity and failure of primary total hip arthroplasty (THA). Furthermore, reports of increased dislocation rate in revision surgery, especially liner exchange, is of concern. Two populations were retrospectively reviewed: Group I, the use of a large diameter metal-on-metal prosthesis in primary and revision THA; and Group II, revision THA for isolated liner exchange via the anterolateral approach.

### Group I

A retrospective review was performed of 329 consecutive patients (377 hips) with varying diagnoses and indications but all receiving a large-diameter metal-on-metal prosthesis. Two surgical approaches were utilized: the anterolateral abductor splitting approach (342 procedures) and a mini-incision posterior approach (35 procedures). All patients were managed on a post-operative protocol. Average age at time of surgery was 55.9 years and average follow up was 3.9 months. The surgical procedures performed included 346 (91.8%) primary procedures, 15 (4.0%) conversion procedures, and 16 (4.2%) revisions or reimplantations after debridement for sepsis. The most common pre-operative diagnoses included 250 hips (66.3%) with osteoarthritis and 46 hips (12.2%) with avascular necrosis. There were 62 (16.4%) patients with high-risk diagnoses for dislocation. The status of all the patients in terms of post-operative dislocation was known for all patients. During the short follow-up period, there were no dislocations. Utilization of large diameter femoral heads and metal-on-metal articulations decreases the risk of dislocations, making this a viable choice for primary and revision procedures.

### Group II

Retrospective analysis of the clinical and radiographic results of twenty-eight patients (29 hips), with a minimum of two-year follow up, who underwent isolated liner exchange for wear and osteolysis performed via the abductor splitting anterolateral approach. The mean follow-up was 39.8 months. Average age at time of surgery was 51.5 years. Pre-operative Harris hip score averaged 68.6 and increased significantly to 79.8 at most recent follow-up ( $p=0.003$ ). Significant improvements in pain and functional scores were also observed ( $p=0.007$  and  $p=0.02$  respectively). The average operating time was 80.7 minutes and the average blood loss was 250.9 cc with only four patients (13.8%) requiring transfusion. No components were re-revised for aseptic loosening and one patient (1 hip) had a dislocation (3.4%). Isolated liner exchange for osteolysis and wear performed via the anterolateral approach has a lower risk of dislocation than previously reported and provides significant improvements in pain, function and total Harris hip score. Continuing to evaluate liner exchange procedures will improve our decision-making process when faced with wear and osteolysis.



*Amelia Munsterman,  
D.V.M. is a Graduate  
Research Associate in  
Veterinary Medicine at  
The Ohio State  
University*

## **ANTI-INFLAMMATORY MECHANISMS OF ALPHA-LINOLENIC ACID ON LIPOPOLYSACCHARIDE-INDUCED EQUINE SYNOVITIS IN VITRO**

Authors: Amelia Munsterman, D.V.M., Alicia Bertone, D.V.M., Ph.D., Terri Zachos, D.V.M., Steven Weisbrode, M.D.

Presenter: Amelia Musterman, D.V.M.

Alpha-linolenic acid (ALA), an n-3 fatty acid, inhibits cytokines and cyclooxygenase production. We evaluated its effects on lipopolysaccharide (LPS)-challenged equine synovial membrane by evaluating hyaluronan (HA), prostaglandin E<sub>2</sub> (PGE<sub>2</sub>), interleukin-1 beta (IL-1b), interleukin-6 (IL-6), thromboxane B<sub>2</sub> (TXB<sub>2</sub>), viability, the phospholipid (PL) profile and histomorphology. Our hypothesis was ALA would reduce inflammatory mediators without negatively altering synovium health (HA production, morphology or viability). Synovial explants were assigned to: normal control (0mg/ml ALA), ALA (5,10,20,50,100 or 300mg/ml), LPS control (1ng/ml LPS; 0mg/ml ALA), or ALA (5,10,20,50,100 or 300mg/ml) with LPS (1ng/ml) and incubated for 24 hours. Culture medium was assayed for cytokines (IL-1, IL-6), eicosanoids (PGE<sub>2</sub>, TBX<sub>2</sub>) and HA. Synovial cell characteristics and PL profiles were assessed. LPS and ALA did not reduce viability or alter histomorphology. ALA increased HA significantly at 50mg/ml ALA (p<0.05). Cytokine production was low in this model, but 100mg/ml ALA further reduced IL-6 concentration (p<0.001). LPS increased TXB<sub>2</sub> and PGE<sub>2</sub>, but ALA inhibited PGE<sub>2</sub> significantly at 300mg/ml ALA (p<0.05). PL analysis showed decreased arachidonic acid (AA) at 300mg/ml ALA (p<0.05), and increased ALA with 100 or 300mg/ml fatty acid (p<0.05). In summary, ALA significantly inhibited cytokine and eicosanoid production in LPS stimulated equine synovium without negatively affecting cellular health. Alterations in the PL profile provide evidence for an alternate pathway for targeting inhibition of inflammatory mediators through their precursors.



*Lynette Mehl, D.P.M.  
is a PGY3 Resident in  
Podiatric Surgery at The  
Ohio State University*

## **TREATMENT OF RECALCITRANT INTERMETATARSAL NEUROMA WITH 4% SCLEROSING ALCOHOL INJECTION**

Authors: Lynette R. Mehl, DPM Christopher F. Hyer, DPM Alan J. Block, DPM Robert VanCourt, DPM

Presenter: Lynette Mehl, D.P.M.

The purpose of this study was to prospectively measure the success of the sclerosing injection for intermetatarsal neuromas in a small pilot group of patients who had failed previous conservative therapies.

This pilot study population consisted of 8 adult subjects with 14 diagnosed intermetatarsal neuromas. Subjects for inclusion were those with the clinical diagnosis of intermetatarsal neuroma in any intermetatarsal space and with previous treatment. 1 ml of sclerosing solution was given using a 1 ¼ inch, 27-gauge needle at a distance of 2 cm proximal to the point of maximum tenderness in the affected intermetatarsal space. There was a minimum of 3 and a maximum of 9 injections, spaced at weekly intervals.

All enrolled subjects completed a pre-treatment survey consisting of both subjective and objective data. Subjective data included demographic data, duration and type of symptoms, treatments used either self or professionally and a pain rating using a visual analog scale (VAS). Objective data included indication of intermetatarsal space involved, point of maximal tenderness (PMT) measured from webspace, positive or negative Mulder's click, Sullivan's sign or Compression test. A similar survey was completed at each weekly visit prior to the next injection. The end point of the study was either; a '0 or 1' reported on the VAS pain scale or when a maximum of 9 injections had been reached.

A final survey was completed at a minimum of 10 months and a maximum of 12 months. This survey consisted of subjective data including a VAS pain rating, percent improvement, duration of relief and whether the patient would recommend the treatment.

Statistical analysis was performed using Microsoft Excel (Redmond, WA). Analysis included improvement of VAS pain score from pre-treatment survey to final follow-up. The mean VAS, mean duration of symptoms, mean duration of relief and mean percent improvement was calculated in both groups from start to finish. Intermetatarsal spaces affected were tabulated and a percent for each intermetatarsal space affected were calculated. All demographic data were tabulated for both groups.

The current study examines a small group of patients with recalcitrant neuroma and shows promising results. A series of weekly 4% sclerosing alcohol injections achieved a subjective success rate of 73% at an average of 11-month follow-up. No complications were encountered with the therapy. Future studies are needed to obtain credible results in a prospective, controlled double-blinded study to increase the strength and confidence of the statistical outcomes of a potentially useful treatment.

---

*The Department of Orthopaedics would like to thank all  
of the presenters for submitting their abstracts for the  
32nd Annual Mallory-Coleman Research Day.*

*We would also like to thank the following for  
making this research day a success:*

***Steven Arnoczky, D.V.M.***

*Visiting Professor and Moderator*

*For lending his time and expertise for our research day*

***Alan Litsky, M.D., ScD.***

*Director of Orthopaedic Research*

*For coordinating the scientific presentations*

***Pfizer, Inc.***

*For generously donating breakfast and lunch*

***Thomas Mallory, M.D. and Carl Coleman, M.D.***

*For financial support of this program*

---

**Please Read Regarding Category I CME Credit  
for This Presentation:**

The Department of Orthopaedics has been authorized by The Ohio State University Center for Continuing Medical Education to provide a total of **six credit hours** in Category I for this research day. In order to receive the full six credits, each attendee must complete two evaluation/attendance forms. One is for the Visiting Professor Grand Rounds and the other is for the research presentations.

We will be collecting these forms throughout the day.