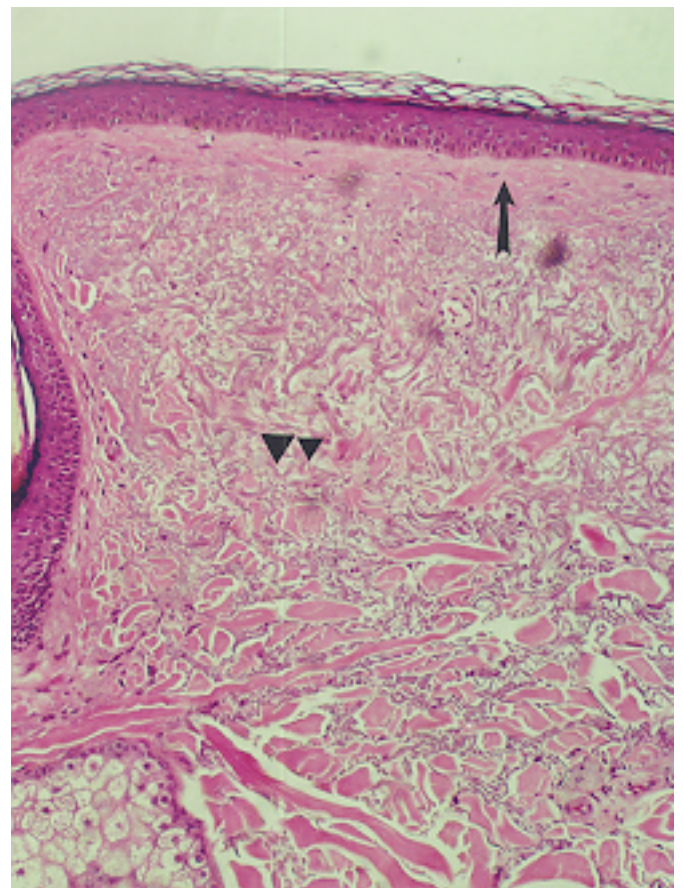


SOLAR (ACTINIC) ELASTOSIS

In skin not regularly exposed to sunlight the papillary dermis gradually loses its elastic tissue with age; in skin exposed to sunlight repeatedly there is a thickened layer of blue-gray elastic fibers (elastosis) just under the epidermis. With elastic tissue stain, this band of basophilic degeneration stains like elastic tissue and thus is called elastotic. Sometimes it appears as interwoven bands of eosinophilic collagen but in cases of severe active degeneration, an amorphous appearance is seen.

Solar elastosis, aggregates of thick interwoven bands of elastotic material (triangles) separated from a flat, somewhat atrophic epidermis by a narrow band of collagen (arrow). A sebaceous gland and part of a hair follicle are present (lower corner).



Solar elastosis, pale or faintly basophilic staining degeneration of collagen. The area of so-called elastosis (arrows) appears amorphous. Mild inflammation is present (triangles).

