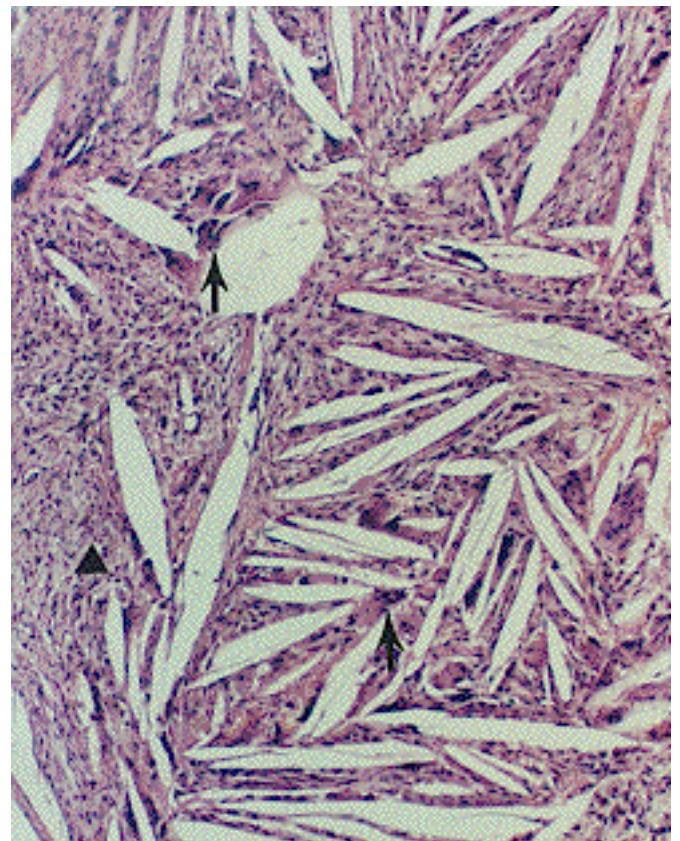


CHOLESTEROL GRANULOMAS

Cholesterol crystal formation may take place in almost any organ as a response to cellular degeneration in association with necrosis, inflammatory disease or prior hemorrhage. In the head and neck area it is commonly seen in association with inflammatory disease of the temporal bone and in atheromatous plaques in blood vessels. Slit-like empty spaces represent cholesterol crystals (fixative dissolved). The crystals are surrounded by large and active looking foreign body giant cells as well as fibrous tissue, macrophages, and lymphoid and plasma cells. Hemosiderin is commonly found alongside the crystals which is not surprising since cholesterol crystals are related to degradation of erythrocytes. The crystalloid spaces should look nearly the same since every crystal of the same species is identical, but fixative processes dissolve the crystals and distort the spaces.

Cholesterol crystals always assume the same shape. Foreign body giant cells (arrows) and fibrous tissue (triangle) are prominent in this cholesterol granuloma from the mastoid, a condition different from cholesteatoma.



Cholesterol granuloma, thyroid, surrounded by fibrous tissue and then thyroid follicles.

