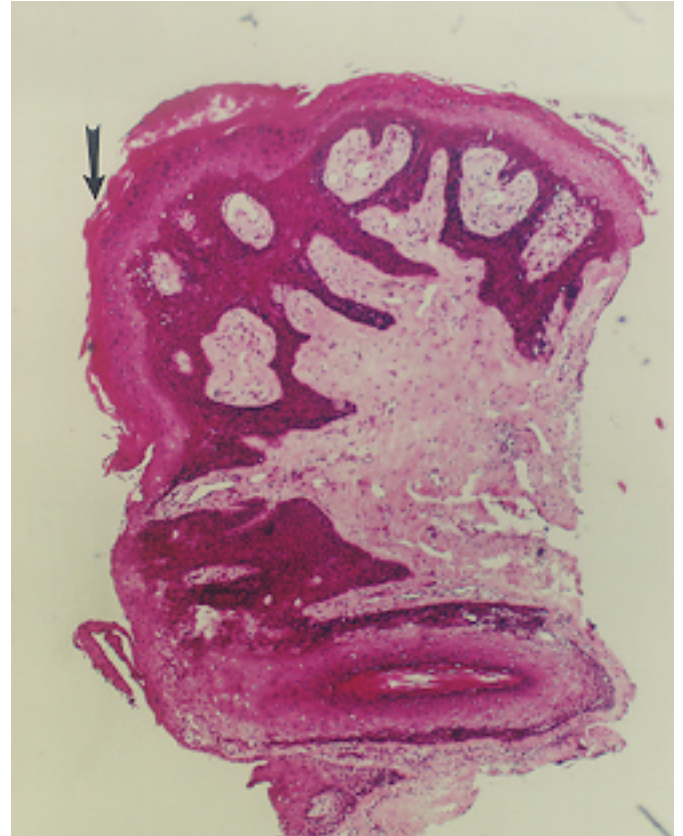


PAPILLOMA

Squamous papilloma is not uncommon in the external auditory meatus, usually just within the meatus. These tumors remain small and are easily treated by excision.

Squamous papilloma, ear canal. Marked hyperkeratosis (arrow) with long, thin rete pegs and fibrous stroma.



Squamous (Schneiderian) papilloma, nasal vestibule. Low power image shows a papillary configuration with marked acanthosis. No dysplasia was seen at high power magnification. VC indicates vascular core.

